



Comparison of complete surgical excision and minimally invasive excision using CO₂ laser for removal of epidermal cysts on the face

Keun Tae Kim,
Hook Sun,
Eui Han Chung

Department of Plastic and
Reconstructive Surgery, Busan Paik
Hospital, Inje University School of
Medicine, Busan, Korea

Original Article

Background: Epidermal cysts are benign, slow growing cysts that often develop on the head, neck, chest, and back of adults. The most common method of surgical excision involves the use of a scalpel and often leaves a scar proportional to the size of the cyst. Therefore, minimally invasive techniques are required. Among these techniques, the CO₂ laser-based technique is minimally invasive and has lower complication rate, shorter recovery times, and lesser scarring. This paper aimed to compare the results and postoperative complications associated with a CO₂ laser-based excision against conventional surgical excision for epidermal cysts.

Methods: We surveyed 120 patients, aged 16 to 65 years, with epidermal cysts on the face measuring 0.5 to 2.2 cm in diameter. Twelve months later, we compared the scar length, recurrence rate, patient satisfaction, and complications between patients treated with CO₂ laser excision versus surgical excision.

Results: The mean scar length (12 months postoperative) after CO₂ laser excision was 0.30 ± 0.15 cm, and that following surgical excision was 1.23 ± 0.43 cm ($p=0.001$). The procedure time (time from incision after local anesthesia to the end of repair) was 16.15 ± 5.96 minutes for CO₂ laser excision versus 22.38 ± 6.05 minutes for surgical excision ($p=0.001$). The recurrence rates in the surgical excision group and CO₂ laser excision group were 3.3% and 8.3%, respectively; this difference was not statistically significant ($p=0.648$).

Conclusion: The cosmetic outcome of CO₂ laser excision is excellent. For epidermal cysts measuring 2.2 cm or smaller, CO₂ laser excision is recommended, especially when aesthetic outcome is considered important.

Keywords: Epidermal cyst / Laser / Surgery, plastic

INTRODUCTION

Epidermal cysts are benign, slow growing cysts that often develop on the head, neck, chest, and back of adults. Surgical indications for epidermal cysts include pain or complications such as inflammation and infection; cosmetic effect is also an indica-

tion for resection [1]. The most common surgical technique is to make an incision using a scalpel on the skin, followed by complete surgical excision. This technique leaves a linear scar proportional to the size of the epidermal cyst [2-8].

Anatomically, the apex of an epidermal cyst is attached to the dermis of the skin. The remaining portion of the epidermal cyst is freely movable and loosely attached to the subcutaneous tissue. Recently, on this anatomical basis, various minimally invasive excision techniques have been introduced. Minimal invasive excision employed in previous studies, include laser punch,

Correspondence: Eui Han Chung

Department of Plastic and Reconstructive Surgery, Busan Paik Hospital, Inje University School of Medicine, 75 Bokji-ro, Busanjin-gu, Busan 47392, Korea
E-mail: jeongyahn@gmail.com

Received September 14, 2018 / Revised February 26, 2019 / Accepted March 3, 2019

and biopsy punch incision. These methods are less invasive than complete surgical excisions; they do not require sutures and minimize scarring, and are thus considered more effective for an epidermal cyst on the face, where a scar is easily visible [3].

The author has been using a CO₂ laser-based method as a minimally invasive excision [4]. As this method creates a small hole in the skin using a CO₂ laser, complications such as hemorrhage or hematoma will be less common compared to techniques requiring an incision. In addition, recovery time is shorter, and the length of the scar, patient satisfaction is also expected to be shorter. This paper aims to compare the results and postoperative complications associated with the CO₂ laser-based excision against conventional surgical excision for epidermal cysts.

METHODS

In Busan Paik Hospital, we surveyed 120 patients, aged 16 to 65 years, with epidermal cysts on the face measuring approximately 0.5–2.2 cm in diameter. This was a retrospective study in which the grouping method was limited to the patients' faces, where the cysts were aesthetically visible. Size of the epidermal cyst was measured using ultrasound by a radiologist. In addition, complete excision and CO₂ laser excision groups were randomly assigned. Exclusion criteria were 3 cm or larger cyst in size, recurring cysts, malignancy cysts, unconfirmed diagnosis, and cysts not on the face.

For treatment of the epidermal cysts, patients were divided into two groups: those treated with a CO₂ laser (60 patients) (Fig. 1) and those treated with conventional surgical excision (60 patients) (Fig. 2). After an average follow-up of 12 months, the scar, recurrence rate, patient satisfaction, and complications were compared between the groups.

The surgical procedure was as follows. First, for the conven-

tional surgical excision, the skin layer was incised elliptically or in a straight line to be removed under local anesthesia, and then exfoliation was carefully carried out using forceps so as not to break the cyst wall, followed by removal of the cyst wall. Next, the incised part was sutured. For the minimally invasive method, a hole of 2–3 mm was made at the pore in the upper part of the cyst using the CO₂ laser. Most of the sebum in the cyst was extracted through the hole by gentle compression with gauze. One leg of a mosquito hemostat was inserted into the cyst, and the cyst wall was gently scraped away toward the hole using the horizontal grooves of the hemostat leg. Then, the skin wound was primarily sutured.

Patients were followed up with a 12-month postoperative office visit to measure the scar length and record complications. All patients were contacted by phone to inquire about recurrence of the cyst after 4 months and 12 months separately.

The Student *t*-test was used to evaluate normality of the data. SPSS software version 11.0 (SPSS Inc., Chicago, IL, USA) was used for statistical analyses. *p*-values less than 0.05 were considered significant.

RESULTS

One hundred and twenty patients, aged 16 to 65 years with ruptured epidermal cysts on the face were included (Table 1). The mean preoperative cyst size for the surgical excision group was 1.31 ± 0.55 cm, and that for the CO₂ laser excision group was 1.20 ± 0.37 cm (*p* = 0.215). The mean scar length in the surgical excision group was 1.23 ± 0.43 cm, and that after CO₂ laser excision was 0.30 ± 0.15 cm (*p* = 0.001). The procedure time (time from incision after local anesthesia to the end of repair) was 16.15 ± 5.96 minutes for the CO₂ laser excision, much shorter than that of the surgical excision group (22.38 ± 6.05 minutes, *p* = 0.001) (Table 2).

Concerning postoperative complications, wound dehiscence developed in two patients in the surgical excision group (3.3%); additional repair was performed for these patients. There were no cases of wound dehiscence in the CO₂ laser excision group, but the difference between the two groups was not statistically significant (*p* = 0.154). Postoperative hematoma was observed

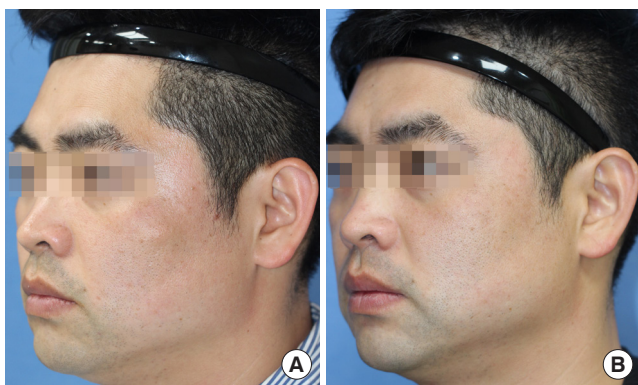

Fig. 1. (A) A 36-year-old male with an epidermal cyst on the left cheek. (B) Patient's photograph 12 months after CO₂ laser excision.

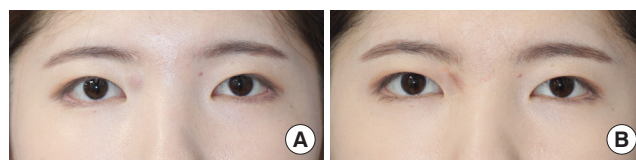

Fig. 2. (A) A 20-year-old female with an epidermal cyst on the upper eyelid. (B) Patient's photograph 12 months after surgical excision.

in three patients in the surgical excision group (5%) and no patients in the CO₂ laser excision group; this difference was not statistically significant ($p=0.079$). The incidence of recurrence with both techniques is shown in Table 3. Early recurrence (0–4 months) rates in the surgical excision and CO₂ laser excision groups were 0% and 3.3%, respectively; however, the difference was not statistically significant ($p=0.672$). Moreover, late recur-

rence (4–12 months) rates in the surgical excision and CO₂ laser excision groups were 3.3% and 5.1%, respectively, but the difference was also not statistically significant ($p=0.683$). Similarly, the recurrence rates during the entire period (0–12 months) in the surgical excision and CO₂ laser excision groups were 3.3% and 8.3%, respectively, but the difference was not statistically significant ($p=0.648$).

All 120 patients were contacted to inquire about their satisfaction with the scar; the results revealed that the CO₂ laser excision group had a significantly higher satisfaction than the surgical excision group (Table 4). There was a statistically significant difference between the complete surgical excision and the CO₂ laser excision group for the mean of the satisfaction scar scale. The difference was statistically significant ($p < 0.05$) (Fig. 3).

Table 1. Patient demographics

	Sex		No. of patients
	Male	Female	
Age (yr)			
16–25	15	17	32
26–35	14	15	29
36–45	13	8	21
46–55	27	3	30
56–65	6	2	8
Total	75	45	120

Table 2. Clinical data for 120 patients with epidermal cysts

Participant data	Complete surgical excision	CO ₂ laser excision	p -value
No. of patients	60	60	-
Size of cysts (cm)	1.31 ± 0.55	1.20 ± 0.37	0.215
Length of scar (cm)	1.23 ± 0.43	0.30 ± 0.15	0.001
Procedure time (min)	22.38 ± 6.05	16.15 ± 5.96	0.001

Values are presented as mean ± standard deviation.

Table 3. Postoperative complications

Outcome	Complete surgical excision (n = 60)	CO ₂ laser excision (n = 60)	p -value
Hematoma	3 (5)	0	0.079
Wound dehiscence	2 (3)	0	0.154
Infection	2 (3)	1 (2)	0.559
Recurrence (mo)			
0–4	0	2 (3)	0.672
4–12	2 (3)	3 (5)	0.683

Values are presented as number (%).

Table 4. Results of satisfaction survey conducted 12 months after surgery

	Satisfaction scar scale				
	Very satisfied	Satisfied	Fair	Dissatisfied	Very dissatisfied
Complete surgical excision	0	14	32	12	2
CO ₂ laser excision	8	41	11	0	0

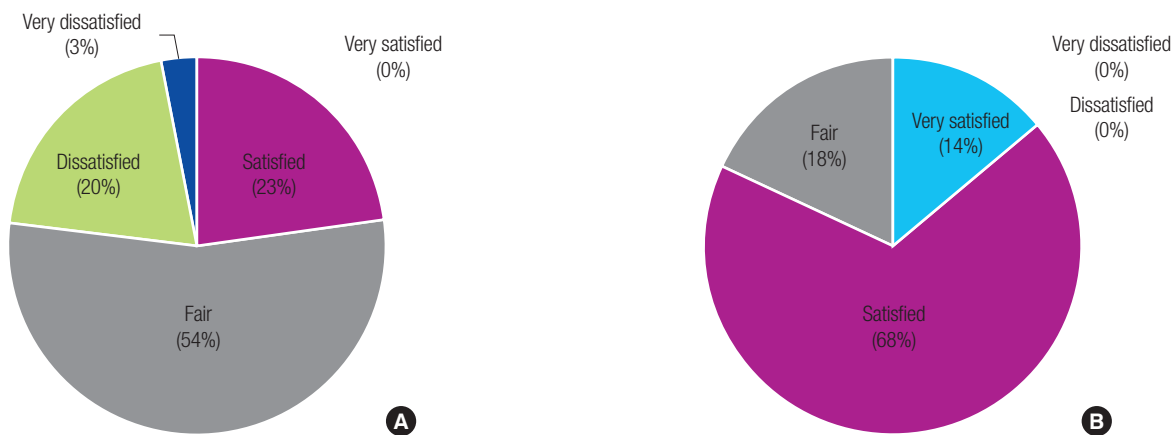


Fig. 3. There was a statistically significant difference between the complete surgical excision and the CO₂ laser excision group for the mean of the satisfaction scar scale. (A) Satisfaction survey result of complete surgical excision after 12 months. (B) Satisfaction survey result of CO₂ laser excision after 12 months. Score of satisfaction scar scale: 5 (very satisfied), 4 (satisfied), 3 (fair), 2 (dissatisfied), 1 (very dissatisfied).

DISCUSSION

Recently, various new methods have been introduced to minimize scarring after surgical removal of epidermal cysts; these include delayed excision of the cystic wall after sebum evacuation by laser punch [3], cyst removal through a minimal incision [5], and cyst removal with a biopsy punch incision [6]. These methods have advantages of simplicity, reduced invasion, less bleeding, reduced scarring, and decreased healing time [8].

Among these minimally invasive techniques, we prefer using CO₂ lasers in our hospital. The reasons are smallest incision size, no risk obstruction of the operative field by bleeding, and reduced risk of complications, such as hematoma. In addition, when perforating the cyst, creating a hole with CO₂ laser allows the operation to be performed more neatly than making an incision with a blade.

The method using CO₂ laser is a slightly modified version of using a stab incision. While the two methods share some similarities, they have distinct differences. First, there is a difference in the incision size. Although the difference in size is small, using CO₂ laser can reduce scarring, which represents a significant difference in aesthetically sensitive areas in the face.

Second, bleeding is unavoidable with a stab incision, which can obscure the field of view. Accordingly, a bigger incision may be required or it may become difficult to neatly remove the cyst. Using CO₂ laser allows bleeding to be controlled simultaneously with the incision. This makes it possible to perform the surgery without obscuring the field of view and allows visual confirmation of the cyst wall, based on which, the cyst wall can be perforated accurately.

The current results show that the minimally invasive method using a CO₂ laser reduced not only the size of the postoperative scar but also operative time; these differences were statistically significant. These results can be a basis to support the use a CO₂ laser as a primary treatment for epidermal cysts on the face, where scars are easily visible. Even for ruptured epidermal cysts, surgery can be considered after creating a hole using a CO₂ laser, extracting pus and then stabilizing the patient so as to reduce scars. CO₂ laser excision, in comparison with other minimally invasive methods (punch biopsy), results in better hemostasis and reduced hematoma development [4].

Wound dehiscence and hematoma, which can occur after surgery for epidermal cyst, were not observed in the group treated with the CO₂ laser excision. However, in comparison with the complete surgical excision group, the difference was statistically insignificant. For minimally invasive excision using a CO₂ laser, a statistically significant difference might be obtained if a greater number of cases were included, as the CO₂

laser can reduce the length of incision and thus improve control of bleeding.

There was no statistically significant difference in the recurrence rate between the two groups. Complete excision can be more difficult with the minimally invasive method using a CO₂ laser compared to surgical excision, and thus may lead to recurrence. In addition, CO₂ laser excision can leave a residual cyst wall that can lead to higher frequency of recurrence than that with the complete excision method. In the present study, a patient suffered from recurrence after a month, which was a case of a ruptured cyst being excised by CO₂ laser, making it difficult to remove completely. Hence, the recurrence appeared early after the procedure.

The present study was conducted for epidermal cysts that were 0.5–2.2 cm in size. If the cyst size is larger or smaller than this, it is expected that there would be smaller scars, regardless of the size, as per the results of the present study; furthermore, CO₂ laser excision would result in higher patient satisfaction than surgical excision.

NOTES

Conflict of interest

No potential conflict of interest relevant to this article was reported.

Ethical approval

The study was approved by the Ethics Review Board of Inje University Health Center (IRB No. 19-0028) and performed in accordance with the principles of the Declaration of Helsinki. Written informed consents were obtained.

Patient consent

The patients provided written informed consent for the publication and the use of their images.

ORCID

Keun Tae Kim <https://orcid.org/0000-0001-7753-739X>

Hook Sun <https://orcid.org/0000-0003-0104-2598>

Eui Han Chung <https://orcid.org/0000-0002-6581-4502>

REFERENCES

1. Zuber TJ. Minimal excision technique for epidermoid (sebaceous) cysts. *Am Fam Physician* 2002;65:1409-20.
2. Avakoff JC. Microincision for removing sebaceous cysts. *Plast Reconstr Surg* 1989;84:173-4.
3. Wu H, Wang S, Wu L, Zheng S. A new procedure for treating a

- sebaceous cyst: removal of the cyst content with a laser punch and the cyst wall with a minimal postponed excision. *Aesthetic Plast Surg* 2009;33:597-9.
4. Song SW, Burm JS, Yang WY, Kang SY. Minimally invasive excision of epidermal cysts through a small hole made by a CO₂ laser. *Arch Plast Surg* 2014;41:85-8.
 5. Yang HJ, Yang KC. A new method for facial epidermoid cyst removal with minimal incision. *J Eur Acad Dermatol Venereol* 2009;23:887-90.
 6. Mehrabi D, Leonhardt JM, Brodell RT. Removal of keratinous and pilar cysts with the punch incision technique: analysis of surgical outcomes. *Dermatol Surg* 2002;28:673-7.
 7. Nakamura M. Treating a sebaceous cyst: an incisional technique. *Aesthetic Plast Surg* 2001;25:52-6.
 8. Alijanpour A, Alijanpour K, Alijanpour K. Comparison of the surgical outcomes of minimal excision and elliptical excision techniques in treating epidermal inclusion cysts: a prospective randomized study. *Shiraz E Med J* 2018;19:e55936.