



# Reconstruction of a small defect of the lower vermilion adjacent to white roll using a modified O-Z flap

Hong Il Kim,  
Ho Sung Kim,  
Jin Hyung Park,  
Hyung Suk Yi,  
Yoon Soo Kim,  
Hyo Young Kim

Department of Plastic and  
Reconstructive Surgery, Kosin  
University Gospel Hospital, Busan,  
Korea

Reconstruction of lip defects is important because the lips play an important role in maintaining aesthetic facial balance, facial expressions, and speech. There are various methods of lip reconstruction such as primary repair, skin grafting, and utilization of local and free flaps. It is important to select a proper reconstruction method according to the size and location of lip defect. Failure to select an appropriate method may result in distortion, color mismatch, sensory loss, and aesthetic imbalance. Herein we present a case of successful aesthetic reconstruction of the lower vermilion. We removed a venous malformation, which was limited to the lower vermilion and adjacent to the white roll, and repaired the defect using the modified O-Z flap.

**Keywords:** Face / Lip / Reconstructive surgical procedures / Surgical flaps

## INTRODUCTION

The lips are made up of various structures comprising multiple layers, such as the skin, subcutaneous tissue, muscle, submucosa, and mucosa. As the lips are important to maintain aesthetic facial balance, facial expressions, and speech, lip reconstruction can be challenging [1]. The vermilion mucosa consists of keratinized and non-keratinized stratified squamous epithelium and shares a boundary with the cutaneous lower lip (white roll). This boundary plays an important role in determining the overall contour of the lip [2].

In cases where reconstruction is necessary to repair a defect caused by trauma or mass excision, the surgeon should select an appropriate reconstruction method according to the size and location of the defect. Inadequate reconstruction may re-

sult in lip distortion, sensory loss, or color mismatch. There are various methods of lip reconstruction such as primary repair, skin grafting, and utilization of local and free flaps. For removing a small mass on the lip, elliptical excision, primary closure, or wedge excision is mainly used. However, the scar formed after excision of a mass located close to or invading the white roll can involve the cutaneous lower lip [3].

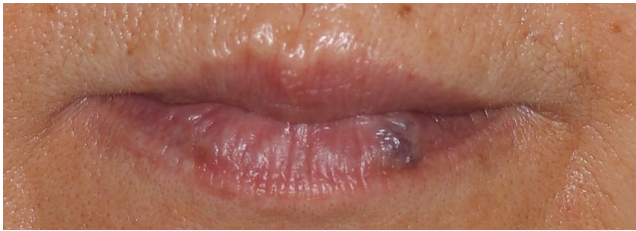In patients who present with a small mass on the lower vermilion adjacent to the white roll, successful aesthetic reconstruction using the modified O-Z flap can be performed. Written informed consent was obtained from the patient for the publication of this case report, and the study was conducted in accordance with the principles of the Declaration of Helsinki.

## CASE REPORT

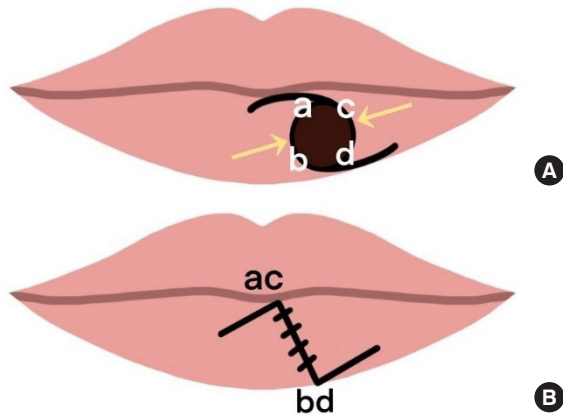
A 60-year-old female patient presented with a mass measuring  $0.7 \times 0.7$  cm on the left lower vermilion (Fig. 1). The patient was diagnosed with a venous lake of the lower vermilion based on the findings of histological examination conducted in the der-

**Correspondence:** Hyo Young Kim  
Department of Plastic and Reconstructive Surgery, Kosin University Gospel  
Hospital, Kosin University College of Medicine, 262 Gamcheon-ro, Seo-gu, Busan  
49267, Korea  
E-mail: hose3290@naver.com

Received April 11, 2021 / Revised June 15, 2021 / Accepted June 20, 2021



**Fig. 1.** Clinical photograph of the patient taken on the first day of consultation in the hospital shows a mass measuring 0.7×0.7 cm on the left lower vermilion adjacent to the white roll.



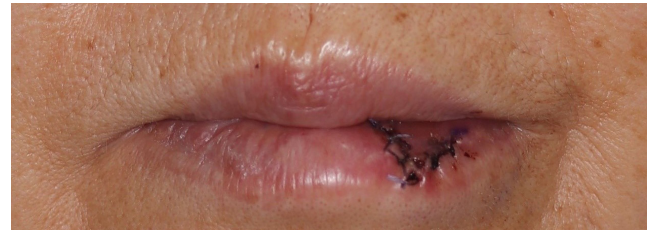**Fig. 2.** Schematic design of the modified O-Z flap. (A) Design of the modified O-Z flap after the resection of the mass. (B) Predicted postoperative approximation; the scar line does not invade the cutaneous lip beyond the white roll.

matology clinic. Initially, pulsed dye laser therapy was prescribed, but the lesion remained unchanged. Therefore, excision of the mass with reconstruction using the modified O-Z flap was planned.

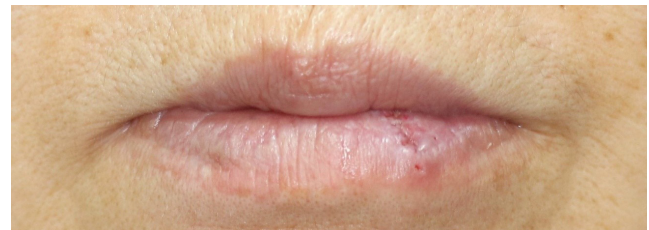As the mass invaded the mucosal layer, it was resected along with this layer. After excision, a curved linear incision was made on both sides of the defect, and each flap was elevated and advanced (Fig. 2). The patient was discharged from the hospital after the surgery, and a simple dressing was applied once every 2 days. Outpatient follow-up examination on postoperative day 3 showed that the wound was healing well without complications such as distortion or necrosis (Fig. 3). Sutures were removed on postoperative day 7, and the patient recovered well (Fig. 4). Histological examination revealed an arteriovenous malformation.

## DISCUSSION

The lips are the starting point of both the gastrointestinal and respiratory systems. Moreover, they are highly visible structures, and an elaborate lip contour defined by structures, such



**Fig. 3.** Clinical photograph taken on postoperative day 3.



**Fig. 4.** Clinical photograph taken on postoperative day 7 shows healing of the lesion without distortion of the vermilion.

as a red-colored vermilion, white roll, and Cupid's bow, plays an important role in the formation of an aesthetic smile. Therefore, when planning lip reconstruction, both functional and aesthetic aspects should be considered [4]. Reconstruction of the lower lip should preserve the sensory function of the lips to prevent sialorrhea and the oral sphincter function for mouth opening [5]. The method of reconstruction must be selected depending on the size and location of the lip defect. In general, primary closure is performed to repair a defect smaller than one-third of the lower lip [6]. However, the scar length in primary closure is more than three times higher than the defect diameter, and the scar may extend beyond the white roll and invade the cutaneous lip [7]. Advancement of the labial mucosa is favored to repair a defect confined to the vermilion and is larger than one-third of the lower lip [8]. However, mucosal advancement is likely to cause complications, such as scar contracture, color mismatch, effacement of the red roll, flattening of the lower lip, superior retraction of the vermilion line, and reduction in the antero-posterior dimension of the lip [9]. In a study by Kim et al. [10], the reconstruction of lower lip defects using a V-Y advancement flap and buccal mucosal graft showed good results; however, lip distortion was observed in some cases because of oral commissure deformity. In a study by Jun et al. [11], the reconstruction of a lower vermilion defect using an anterior ventral tongue flap produced good results in terms of aesthetic and functional aspects. However, this two-stage procedure was difficult to perform due to possible postoperative bite injuries and the characteristics of the surgical method.

The O-Z flap is useful for closing circular defects or for the reconstruction of a convex-shaped area. It is especially useful for the reconstruction of facial defects in various sites, such as the forehead, scalp, temple, and upper eyelids, because it has the effect of Z-plasty, which produces minimal distortion. The use of the O-Z flap is advantageous for the reconstruction of vermilion defects, which can cause functional and aesthetic imbalances, even in case of small distortions.

The O-Z flap is a double rotation flap that divides the pedicle in the direction opposite to the defect. For an optimal design of the O-Z flap to minimize distortion, the planned incision line should form an acute angle of 45° with the center of the defect, and the incision length should be approximately twice the defect diameter [12]. However, the original method would have had a poor aesthetic outcome in our case because the scar would have extended beyond the white roll and invaded the cutaneous lip. Therefore, we developed the modified O-Z flap method. To design the modified O-Z flap, referring to the oval-to-z flap method and applying to circular defect, both the methods were combined to set the ratio of the scar length to defect diameter at 1:1, and the curved linear incision line was designed perpendicular to the center of the defect [13]. The modified O-Z flap method resulted in a better aesthetic outcome compared with the conventional O-Z flap method by confining the scar line within the vermilion while minimizing distortion.

In conclusion, the reconstruction of small defects adjacent to the white roll using the modified O-Z flap is a good treatment option as it provides both aesthetic and functional benefits.

## NOTES

### Conflict of interest

No potential conflict of interest relevant to this article was reported.

### Ethical approval

The study was approved by the Institutional Review Board of Kosin University Gospel Hospital (IRB No. KUGH-2020-11-027) and performed in accordance with the principles of the Declaration of Helsinki. Written informed consent was obtained.

### Patient consent

The patient provided written informed consent for the publication and the use of her images.

### ORCID

Hong Il Kim <https://orcid.org/0000-0002-5505-9945>

Ho Sung Kim <https://orcid.org/0000-0002-6030-3199>  
 Jin Hyung Park <https://orcid.org/0000-0001-9415-2467>  
 Hyung Suk Yi <https://orcid.org/0000-0002-9584-8201>  
 Yoon Soo Kim <https://orcid.org/0000-0002-8073-5511>  
 Hyo Young Kim <https://orcid.org/0000-0002-1834-5766>

### Author contribution

Conceptualization: HYK. Data curation: HIK Formal analysis: YSK. Methodology: HIK, JHP, HSY, HIK, HYK. Supervision: HYK. Validation: YSK. Writing - original draft: HIK. Writing - review & editing: JHP, HSY, HIK, YSK, HYK.

## REFERENCES

- Nabili V, Knott PD. Advanced lip reconstruction: functional and aesthetic considerations. *Facial Plast Surg* 2008;24:92-104.
- Pribaz JJ, Meara JG, Wright S, Smith JD, Stephens W, Breuing KH. Lip and vermilion reconstruction with the facial artery musculomucosal flap. *Plast Reconstr Surg* 2000;105:864-72.
- Chang CS, Wong A, Rohde CH, Ascherman JA, Wu JK. Management of lip hemangiomas: Minimizing peri-oral scars. *J Plast Reconstr Aesthet Surg* 2012;65:163-8.
- Ozdemir R, Ortak T, Kocer U, Celebioglu S, Sensoz O, Tiftikcioglu YO. Total lower lip reconstruction using sensate composite radial forearm flap. *J Craniofac Surg* 2003;14:393-405.
- Zilinsky I, Winkler E, Weiss G, Haik J, Tamir J, Orenstein A. Total lower lip reconstruction with innervated muscle-bearing flaps: a modification of the Webster flap. *Dermatol Surg* 2001;27:687-91.
- Yotsuyanagi T, Yokoi K, Urushidate S, Sawada Y. Functional and aesthetic reconstruction using a nasolabial orbicularis oris myocutaneous flap for large defects of the upper lip. *Plast Reconstr Surg* 1998;101:1624-9.
- Lee TS, Murakami CS, Suryadevara AC. Tissue conservation using circular defect with dog-ear deformities excision technique. *Laryngoscope* 2011;121:2299-304.
- Coppit GL, Lin DT, Burkey BB. Current concepts in lip reconstruction. *Curr Opin Otolaryngol Head Neck Surg* 2004;12:281-7.
- Sand M, Altmeyer P, Bechara FG. Mucosal advancement flap versus primary closure after vermilionectomy of the lower lip. *Dermatol Surg* 2010;36:1987-92.
- Kim JH, Ahn CH, Kim S, Lee WS, Oh SH. Effective method for reconstruction of remaining lower lip vermilion defect after a mental V-Y advancement flap. *Arch Craniofac Surg* 2019;20:76-83.
- Jun G, Wei F, Tong L, Yi H, Hao Z, Jun LS. Aesthetic and functional evaluation of large full-thickness vermilion and lower lip

- defects reconstruction. *J Craniofac Surg* 2019;30:e36-9.
12. Buckingham ED, Quinn FB, Calhoun KH. Optimal design of O-to-Z flaps for closure of facial skin defects. *Arch Facial Plast Surg* 2003;5:92-5.
  13. Rahim RR, Gardner LS, Langtry JA. Oval-to-Z flap: a novel option in cutaneous reconstruction. *Dermatol Surg* 2013;39:1398-400.