



Reconstruction of large facial defects using a combination of forehead flap and other procedures

Ryuck Seong Kim¹, Changryul Yi^{1,2}, Hoon Soo Kim³, Ho Yoon Jeong¹, Yong Chan Bae^{1,2}

¹Department of Plastic and Reconstructive Surgery, Pusan National University School of Medicine, Busan; ²Biomedical Research Institute, Pusan National University Hospital, Busan; ³Department of Dermatology, Pusan National University School of Medicine, Busan, Korea

Original Article

Background: Reconstruction of large facial defects is challenging as both functional and cosmetic results must be considered. Reconstruction with forehead flaps on the face is advantageous; nonetheless, reconstruction of large defects with forehead flaps alone results in extensive scarring on the donor site. In our study, the results of reconstruction using a combination of forehead flaps and other techniques for large facial defects were evaluated.

Methods: A total of 63 patients underwent reconstructive surgery using forehead flaps between February 2005 and June 2020 at our institution. Reconstruction of a large defect with forehead flaps alone has limitations; because of this, 22 patients underwent a combination of procedures and were selected as the subjects of this study. This study was retrospectively conducted by reviewing the patients' medical records. Additional procedures included orbicularis oculi musculocutaneous (OOMC) V-Y advancement flap, cheek advancement flap, nasolabial V-Y advancement flap, grafting, and simultaneous application of two different techniques. Flap survival, complications, and recurrence of skin cancer were analyzed. Patient satisfaction was evaluated using questionnaires.

Results: Along with reconstructive surgery using forehead flaps, nasolabial V-Y advancement flap was performed in nine patients, local advancement flap in three, OOMC V-Y advancement flap in two, grafting in five, and two different techniques in three patients. No patient developed flap loss; however, cancer recurred in two patients. The overall patient satisfaction was high.

Conclusion: Reconstruction with a combination of forehead flaps and other techniques for large facial defects can be considered as both functionally and cosmetically reliable.

Abbreviations: BCC, basal cell carcinoma; FTSG, full thickness skin graft; MMS, Mohs microscopic surgery; OOMC, orbicularis oculi musculocutaneous; STSG, split thickness skin graft

Keywords: Basal cell carcinoma / Reconstructive surgical procedures / Skin neoplasms / Squamous cell carcinoma / Surgical flaps

Correspondence: Yong Chan Bae

Department of Plastic and Reconstructive Surgery, Pusan National University School of Medicine and Biomedical Research Institute, Pusan National University Hospital, 179 Gudeok-ro, Seo-gu, Busan 49241, Korea
E-mail: baeyc2@hanmail.net

This work was supported by a clinical research grant from Pusan National University Hospital in 2021.

How to cite this article:

Kim RS, Yi C, Kim HS, Jeong HY, Bae YC. Reconstruction of large facial defects using a combination of forehead flap and other procedures. Arch Craniofac Surg 2022;23(1):17-22. <https://doi.org/10.7181/acfs.2021.00381>

Received August 20, 2021 / Revised September 6, 2021 / Accepted December 16, 2021

INTRODUCTION

Facial skin structure varies based on creases, wrinkles, and skin thickness; hence, satisfactory cosmetic and functional reconstruction of large defects in the facial area poses a challenge even to experienced plastic surgeons [1]. Facial reconstruction can be performed using primary closure, local flap, distant flap, or free flap. It depends on various factors, such as the size and location of the defects, and the condition of adjacent tissues. However, skin grafting has both functional and cosmetic limi-

tations; it can result in postoperative deformation due to contraction, and color mismatch with the surrounding skin [2]. Free-flap reconstruction can be performed for large defects with favorable functional results. Nonetheless, it achieves low patient satisfaction because of cosmetic reasons owing to scarring, and it is a burdening reconstruction procedure given that most patients with skin cancer are older patients [3,4].

Forehead flaps are natural and durable axial flaps that are supplied with blood by the supraorbital or supratrochlear blood vessels. Moreover, they are suitable donor flaps for the facial skin, as the color and texture match the facial skin [5,6]. In addition, regarding donor site scar formation and deformation, previous studies have reported satisfactory results for forehead flap reconstruction with primary closure [7]. Considering these features, it is possible to cover a large defect on the midface by designing various shapes on the forehead as necessary; however, if a large defect is reconstructed with only the forehead flap, it is impossible to cover a large defect on the forehead by primary closure. Eventually, a scar that is not cosmetically satisfactory in the forehead is generated, causing the surgeon to hesitate.

Skin thicknesses and folds vary; hence, bulging deformities may occur after single forehead flap application at locations with thin skin, such as the eyelids and the boundary between the nose and cheeks [8]. Considering these problems, if satisfactory reconstruction cannot be achieved with only one forehead flap, the aforementioned weakness can be compensated using other reconstruction techniques simultaneously. Therefore, a combination of procedures can completely cover the defect while reducing the width of the forehead flap and aiding primary closure of the donor site. We decided to introduce our method because we have obtained satisfactory results by combining various procedures for covering large defects in the facial area.

METHODS

Reconstruction with forehead flaps was performed in 63 patients between February 2005 and June 2020 at our institution. Out of 63 patients, 22 underwent a combination of forehead flap reconstruction and another procedure. These 22 patients were retrospectively evaluated using chart reviews and questionnaires. This study was approved by the institutional review board, and informed consent was obtained from all patients and caregivers.

The selected patients included 10 men and 12 women, with an average age of 68 years (range, 45–91 years). The diagnosis was basal cell carcinoma (BCC) in 19 patients and squamous cell carcinoma in three patients, with the occurrence of soft tissue defects following Mohs microscopic surgery (MMS). Twen-

ty patients had primary cancerous lesions, whereas two patients had recurrence following treatment for skin cancer. Additional procedures included nasolabial V-Y advancement flap, orbicularis oculi musculocutaneous (OOMC) V-Y advancement flap, local advancement flap, grafting, and simultaneous application of two techniques. The follow-up period for the 22 selected patients ranged from 6 to 180 months. Their mean follow-up period was 28 months.

Major postoperative complications including flap loss, and minor complications such as partial necrosis, hematoma, infection, and dehiscence, were analyzed through chart reviews. Patient satisfaction with the surgical results was evaluated using questionnaires. This survey was conducted to confirm the satisfaction judged by the patient. Patient satisfaction questionnaire survey was assessed based on contour, color matching, and scar formation. Responses were assessed on a 5-point scale for each item (1 = very dissatisfied, 2 = dissatisfied, 3 = fair; 4 = satisfied, 5 = very satisfied) [9,10]. Answers were provided by the patients themselves in 18 cases; however, in three cases, evaluation was performed based on the responses provided by their closest caregivers because of the inability of the patients to communicate. Postoperative evaluation was performed after 6 months at the earliest.

RESULTS

Among 63 patients who underwent reconstructive surgery using forehead flaps, 22 patients (approximately 35%) underwent a combination of procedures. Reconstruction with median and paramedian forehead flaps was performed in 15 and 7 patients, respectively. Additional procedures using local flaps—nasolabial V-Y advancing flap, local advancing flap, and OOMC V-Y advancing flap—were performed in nine, three, and two patients, respectively. Five patients underwent grafting, which included split-thickness skin grafting in two patients and separate full-thickness skin grafting, composite grafting, and mucosal grafting in one patient each. The remaining three patients underwent a combination of the forehead flap and two different additional techniques. The combination of procedures performed in these three patients was as follows: OOMC V-Y advancement flap with nasolabial V-Y advancement flap; two OOMC V-Y advancement flaps from the upper and lower eyelids; and right nasolabial transposition flap and left nasolabial rotation advancement flap (Table 1).

Postoperatively, major complications (e.g., flap loss) and minor complications (e.g., partial necrosis, hematoma, infection, dehiscence) were absent in all the patients who underwent the procedures. Three patients complained of nasal obstruction

and rhinorrhea after surgery; among them, symptoms of nasal obstruction in one patient improved after revision surgery. The causative cancer (BCC) recurred in two patients in whom reconstruction was performed using a combination of forehead flaps and grafting.

Postoperative satisfaction was evaluated in 18 patients. The scores, represented as mean ± standard deviation, were 3.55 ± 1.19 for contour, 3.94 ± 0.99 for color match, and 3.66 ± 1.18 for scar formation (Table 2). The total score obtained was 11.17 ± 2.83 out of 15. The total scores observed with different techniques were as follows: nasolabial V-Y advancement flap: 11.25 ± 3.01, local advancement flap: 12.67 ± 1.53, OOMC V-Y advancement flap: 13.00 ± 1.41, and grafting: 10.50 ± 0.70. Furthermore, patients who underwent a combination of two dif-

Table 1. Summary of combination surgeries

Technique performed in addition to forehead flap	Total
Nasolabial advancement flap	9
Local advancement flap	3
OOMC V-Y advancement flap	2
Grafting (2 STSG, 1 FTSG, 1 composite graft, 1 mucosal graft)	5
Two different techniques	3
Total	22

OOMC, orbicularis oculi musculocutaneous; STSG, split thickness skin graft; FTSG, full thickness skin graft.

Table 2. Postoperative assessment of patient satisfaction with contour, color matching, and scar formation

Characteristics	Satisfaction value, mean ± SD
Contour	3.55 ± 1.19
Color match	3.94 ± 0.99
Scar formation	3.66 ± 1.18

Responses were assessed on a 5-point scale for each item (1 = very dissatisfied, 2 = dissatisfied, 3 = fair; 4 = satisfied, 5 = very satisfied).

ferent techniques reported a total score of 8.33 ± 3.78 (Table 3).

Whereas the eyelid skin is thin, the skin covering the nose and the cheeks is relatively thick. If a defect involving the eyelids as shown in Fig. 1 would be reconstructed with a forehead flap only, a bulging deformity may occur. Moreover, the large width of the defect (3 cm), would make primary closure difficult, if the forehead flap would be elevated without width reduction. As shown in Fig. 1, OOMC flaps were used on the upper and lower eyelids to cover the thin skin eyelid and reduce the width of the defect. Subsequently, the remaining defect was reconstructed with a forehead flap.

When a major defect occurs in the nose, the forehead flap can be an excellent reconstruction tool. However, if the defect involves both the nose and a cheek, as shown in Fig. 2, it is difficult to reproduce an alar groove with a forehead flap only. Therefore, the nose was reconstructed with a forehead flap after using a cheek flap for delineation of the alar groove (Fig. 2).

Table 3. Postoperative assessment of patient satisfaction according to the technique performed in addition to the forehead flap

Technique performed in addition to the forehead flap	Total satisfaction value, mean ± SD
Nasolabial advancement flap	11.25 ± 3.01
Local advancement flap	12.67 ± 1.53
OOMC V-Y advancement flap	13.00 ± 1.41
Grafting	10.50 ± 0.70
Two different techniques	8.33 ± 3.78

Responses were assessed on a 5-point scale for each item (1 = very dissatisfied, 2 = dissatisfied, 3 = fair; 4 = satisfied, 5 = very satisfied) and total score is out of 15. OOMC, orbicularis oculi musculocutaneous flap.

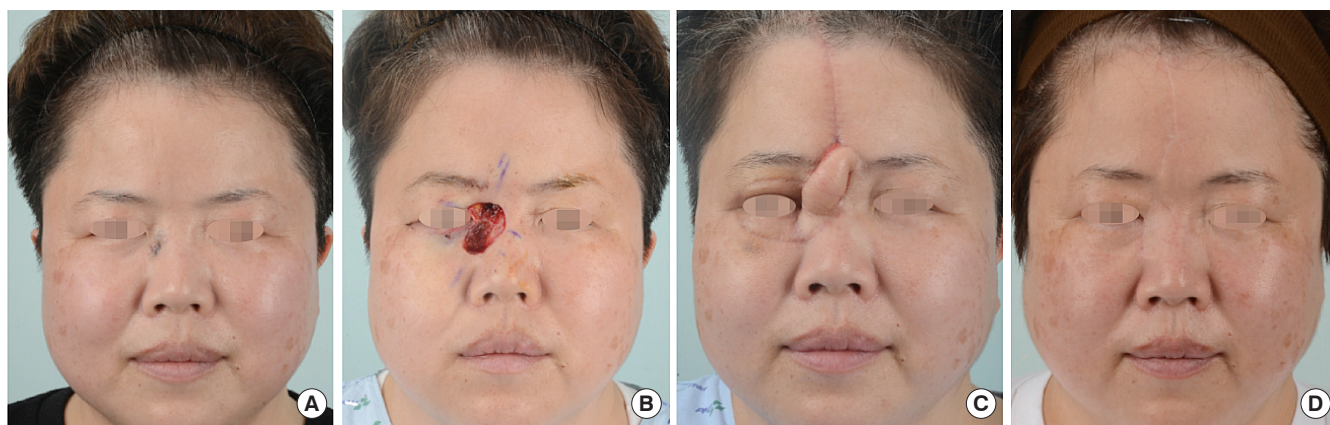

Fig. 1. A 48-year-old woman, whose primary diagnosis was nevus, was finally diagnosed as basal cell carcinoma. (A) Preoperative photograph. (B) Intraoperative photograph after excision of the tumor. (C) Reconstruction using an orbicularis oculi musculocutaneous advancement and a forehead flap. (D) Follow-up photograph 1 year and 6 months after surgery.

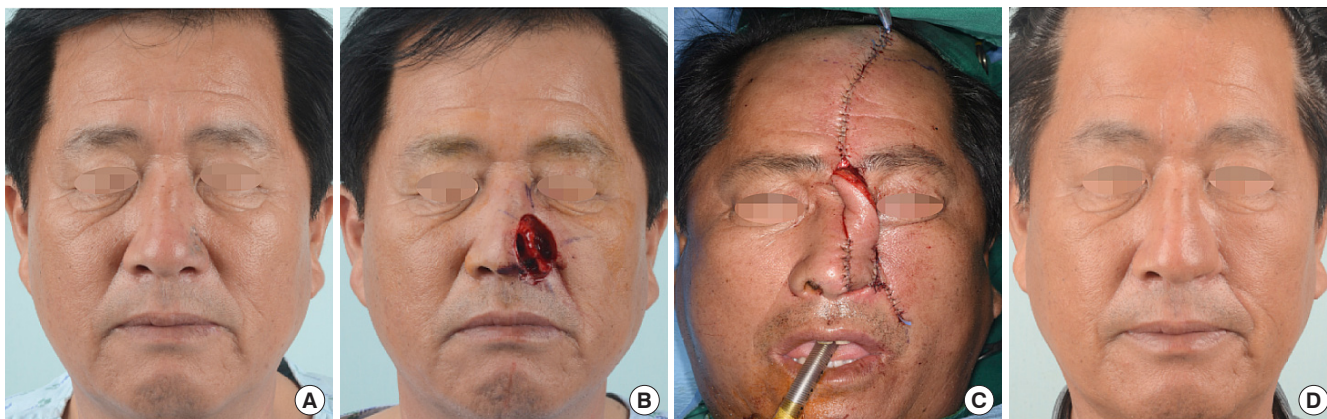


Fig. 2. A 54-year-old man with a hyperpigmented papule, which was diagnosed as basal cell carcinoma. (A) Preoperative photograph. (B) Intraoperative photograph after excision of the tumor. (C) Reconstruction using a cheek advancement and a forehead flap. (D) Follow-up photograph 1 year after surgery.

DISCUSSION

A considerable number of the literature available on forehead flaps were based on concepts, techniques, and applications [11]; to the best of our knowledge, no paper has reported the results of reconstructive surgery for large defects using a combination of forehead flaps and various techniques.

Forehead flaps are versatile and reliable and can be utilized through various approaches; hence, reconstruction of large defects has been performed using forehead flaps alone, such as total nasal reconstruction with forehead flaps. However, an attempt to cover a large defect with only the forehead flap will inevitably result in a large scar on the donor site [8,12,13]. To reconstruct the donor site with such a large defect, it can be left to heal secondarily or a skin graft can be performed. Considering this, the drawback of having a large scar on the forehead is unavoidable. The results at both donor and recipient sites were considered important. Therefore, we aimed to design the forehead flap with primary closure in mind.

Plastic surgeons should attempt to achieve a delicate balance between the application of various flap techniques for reconstruction and prevention of potential morbidity to the donor site [4]. If large defects are reconstructed with a single flap, increased tension would arise during closure of the donor site; hence, wound dehiscence or hypertrophic scar formation may occur. If the defects are not closed, contractures or large scar formations may occur due to secondary healing or use of skin grafts [14]. Santos Stahl et al. [15] and Little et al. [16] reported an approximately 5% increase in the rate of skin necrosis after a forehead flap. Skin necrosis was however not noted in any of our patients. Primary closure was possible for all donor sites. The reason for this difference is thought to be that the forehead flap was not ex-

cessively used by reducing the size of the defect with additional procedures. Taking a lot of tissue from the donor site and reconstructing it on the defect site can be a satisfactory result for the recipient site. However, the surgeon must keep in mind that damage will obviously occur to the donor site [17].

In cases with large defects that cannot be sufficiently reconstructed using local flaps, a skin graft or free flap may be used. However, skin grafts result in a typical patchy appearance because of the color mismatch and contour differences; thus, it produces a cosmetically unsatisfactory outcome [2,18,19]. In addition, it has a low functional satisfaction due to loss of elasticity and graft retraction. Reconstruction with free flaps is a promising technique for deep and wide defects. However, it requires considerable technical expertise, and it is considered time-consuming even by experienced surgeons [4]. Patients with skin cancer are generally of older age; thus, special attention must be paid to their general conditions [20]. The occurrence of contour changes, scar formations, color mismatches, and deformations following surgery are the main disadvantages of using free flaps [3]. Both skin grafting and the free flap method require long-term dressing; hence, they require a long hospital stay, which is another disadvantage.

Statistical analysis was not possible due to the insufficient number of patients; nevertheless, the lowest score was recorded when two different techniques were used. In this case, “forehead flap+ α ” was not considered to be sufficient; hence, “forehead flap+ α + β ” was used. Among the scoring categories, it received a relatively low score with respect to contour. It is thought that the cause of this result is that the size of the defect is large enough to require “+ β .” Patients with low scores generally complained of discomfort due to bulging deformities. It is disproved by the fact that contour shows the lowest value among the three

categories. Patients who complained like this recommended revision operation 6 months after surgery.

A study limitation is that we did not compare the operation with the forehead flap alone. In our hospital, the forehead flap was only used when it was determined that primary closure of the donor site was possible. In the end, the forehead flap was used alone only when the defect size was small. The size of the defect determines if only a forehead flap or a combination of a forehead flap and other procedures is used. Considering this size difference, comparing the two groups is inevitably biased.

To reconstruct the defect that occurred after MMS due to skin cancer, the surgeon should be able to use various reconstruction methods. Since the skin of the face has various creases, wrinkles, and skin thicknesses, it is necessary to cover it using various flaps around it to increase the satisfaction after surgery. It is difficult to express the diversity of thickness and boundaries with only one flap for a large defect. Therefore, we used various flaps for reconstruction and achieved satisfactory outcomes.

In this study, reconstructive surgery using a combination of forehead flaps and other procedures was performed for large facial defects after MMS in patients with skin cancer because reconstruction with forehead flaps alone was considered to be challenging. The operator can obtain satisfactory cosmetic and functional results by learning various surgical methods and applying the combined technique for reconstruction of large facial defects.

NOTES

Conflict of interest

Yong Chan Bae is an editorial board member of the journal but was not involved in the peer reviewer selection, evaluation, or decision process of this article. No other potential conflicts of interest relevant to this article were reported.

Ethical approval

The study was approved by the Institutional Review Board of Pusan National University Hospital (IRB No. 2103-006-100) and performed in accordance with the principles of the Declaration of Helsinki. Written informed consent was obtained.

Patient consent

The patients provided written informed consent for the publication and the use of their images.

ORCID

Ryuck Seong Kim <https://orcid.org/0000-0002-5753-7699>
Changryul Yi <https://orcid.org/0000-0002-4633-0043>

Hoon Soo Kim <https://orcid.org/0000-0002-7649-1446>
Ho Yoon Jeong <https://orcid.org/0000-0003-1837-9146>
Yong Chan Bae <https://orcid.org/0000-0002-0268-4667>

Author contribution

Conceptualization: Yong Chan Bae. Methodology: Yong Chan Bae. Project administration: Yong Chan Bae. Formal analysis: Changryul Yi. Data curation: Hoon Soo Kim. Visualization: Ho Yoon Jeong. Investigation: Ryuck Seong Kim. Writing - original draft: Ryuck Seong Kim. Writing - reviewing and editing: Ryuck Seong Kim. All authors read and approved the final manuscript.

REFERENCES

1. Russo F, Linares M, Iglesias ME, Martinez-Amo JL, Cabo F, Tercedor J, et al. Reconstruction techniques of choice for the facial cosmetic units. *Actas Dermosifiliogr* 2017;108:729-37.
2. Lee KS, Kim JO, Kim NG, Lee YJ, Park YJ, Kim JS. A comparison of the local flap and skin graft by location of face in reconstruction after resection of facial skin cancer. *Arch Craniofac Surg* 2017;18:255-60.
3. Menick FJ. Facial reconstruction with local and distant tissue: the interface of aesthetic and reconstructive surgery. *Plast Reconstr Surg* 1998;102:1424-33.
4. Ji C, Li R, Shen G, Zhang J, Liang W. Multiple pedicled flaps cover for large defects following resection of malignant tumors with partition concept. *Medicine (Baltimore)* 2017;96:e7455.
5. Correa BJ, Weathers WM, Wolfswinkel EM, Thornton JF. The forehead flap: the gold standard of nasal soft tissue reconstruction. *Semin Plast Surg* 2013;27:96-103.
6. Menick FJ. Nasal reconstruction with a forehead flap. *Clin Plast Surg* 2009;36:443-59.
7. Choi JS, Bae YC, Nam SB, Bae SH, Kim GW. Evaluation of the donor site after the median forehead flap. *Arch Plast Surg* 2018;45:259-65.
8. Burget GC, Walton RL. Optimal use of microvascular free flaps, cartilage grafts, and a paramedian forehead flap for aesthetic reconstruction of the nose and adjacent facial units. *Plast Reconstr Surg* 2007;120:1171-207.
9. Chang JW, Lim JH, Lee JH. Reconstruction of midface defects using local flaps: an algorithm for appropriate flap choice. *Medicine (Baltimore)* 2019;98:e18021.
10. Lee YJ, Lee KT, Pyon JK. Finger reduction of nasal bone fracture under local anesthesia: outcomes and patient reported satisfaction. *Arch Craniofac Surg* 2019;20:24-30.
11. Pawar SS, Kim MM. Updates in forehead flap reconstruction of facial defects. *Curr Opin Otolaryngol Head Neck Surg* 2013;

- 21:384-8.
12. Fan J. A new technique of scarless expanded forehead flap for reconstructive surgery. *Plast Reconstr Surg* 2000;106:777-85.
 13. Elshamma NA, Al Qabbani A, Alkatan HM, Al-Qattan MM. The use of forehead flaps in the management of large basal cell carcinomas of the medial canthus/medial lower eyelid in Saudi patients. *Saudi J Ophthalmol* 2013;27:223-5.
 14. Lee DM, Bae YC, Nam SB, Bae SH, Choi JS. Reconstruction of large facial defects via excision of skin cancer using two or more regional flaps. *Arch Plast Surg* 2017;44:319-23.
 15. Santos Stahl A, Gubisch W, Fischer H, Haack S, Meisner C, Stahl S. A cohort study of paramedian forehead flap in 2 stages (87 flaps) and 3 stages (100 flaps). *Ann Plast Surg* 2015;75:615-9.
 16. Little SC, Hughley BB, Park SS. Complications with forehead flaps in nasal reconstruction. *Laryngoscope* 2009;119:1093-9.
 17. Kim GW, Bae YC, Bae SH, Nam SB, Lee DM. A clinical review of reconstructive techniques for patients with multiple skin cancers on the face. *Arch Craniofac Surg* 2018;19:194-9.
 18. Wollina U. Reconstruction of large facial defects after delayed Mohs surgery for skin cancer. *Acta Dermatovenerol Croat* 2015;23:265-9.
 19. Park YJ, Kwon GH, Kim JO, Ryu WS, Lee KS. Reconstruction of nasal ala and tip following skin cancer resection. *Arch Craniofac Surg* 2019;20:382-7.
 20. Suh JM, Chung CH, Chang YJ. Head and neck reconstruction using free flaps: a 30-year medical record review. *Arch Craniofac Surg* 2021;22:38-44.